

HEAD AND NECK

Immediate revision in patients with bilateral recurrent laryngeal nerve palsy after thyroid and parathyroid surgery. How worthy is it?

Ruolo dell'immediata revisione chirurgica nei pazienti con paralisi laringea bilaterale dopo tiroidectomia e chirurgia delle paratiroidi

M. ZÁBRODSKÝ, J. BOUČEK, J. KASTNER, M. KUČAŘ, M. CHOVANEC, J. BETKA

Charles University in Prague, First Faculty of Medicine, Department of Otorinolaryngology, Head and Neck Surgery, Faculty Hospital Motol, Postgraduate Medical School, Czech Republic

SUMMARY

The aim of the present study was to determine whether immediate revision surgery has benefits for patients with iatrogenic bilateral recurrent laryngeal nerve (RLN) palsy. From January 1, 2004 to January 30, 2011, 29 consecutive patients underwent immediate revision after total thyroidectomy. The cohort comprised 29 patients, 2 males and 27 females, aged 23 to 76 years (median 52 years). Identification of the type and extent of injury of each branch was reported in the protocol, and reconstruction was performed whenever possible. A complete transection of the nerve or one of its branches was found in 14 and 5 nerves, respectively. In three patients, the nerve was completely or partially transected on both sides. Seven anatomically intact nerves were injured by loaded ligature, in one case there was a sign of thermal damage and four nerves showed signs of excessive manipulation (thinning of the nerve trunk). Primary end-to-end anastomosis was performed in seven completely transected RLN and four transected anterior branches of RLN. None of the reconstructed nerve trunks or its branches regained function, although good muscle tone was observed. 23 of 38 intact nerves (61%) regained function, and normal vocal-cord mobility on both sides was restored in only four patients. In all cases with regained vocal-cord mobility, functional recovery occurred within 3 months after primary surgery. In conclusion, immediate revision after thyroidectomy may help to indicate the type of RLN damage, which is a predictor of functional recovery and one of major factors influencing future therapeutic management.

KEY WORDS: Bilateral recurrent laryngeal nerve palsy • Immediate revision • Functional recovery • Thyroid surgery

RIASSUNTO

Obiettivo del presente studio è stato quello di determinare se la revisione immediata potrebbe essere utile nei pazienti affetti da paralisi ricorrente bilaterale dopo chirurgia tiroidea o delle ghiandole paratiroidi. Dal 1° gennaio 2004 al 30 gennaio 2011, 29 pazienti consecutivi sono stati sottoposti a revisione immediata dopo tiroidectomia totale e sono stati inclusi nello studio. La coorte comprendeva 2 maschi e 27 femmine, di età compresa tra 23-76 anni (età mediana 52 anni). L'identificazione del tipo e dell'estensione del danno del nervo ricorrente o di uno dei suoi rami è stata riportata nello studio. Quando possibile è stata eseguita la ricostruzione. Una resezione completa del nervo o di uno dei suoi rami è stata trovata in 14 e 5 casi, rispettivamente. In tre pazienti il nervo è stato tutto o in parte sezionato bilateralmente. In sette casi il nervo anatomicamente intatto è stato danneggiato da legatura in prossimità dello stesso, in un caso erano riconoscibili i segni di danno termico. In quattro nervi sono stati identificati segni di manipolazione eccessiva. Un'anastomosi primaria terminale è stata effettuata in sette nervi laringei completamente sezionati e in quattro rami anteriori dello stesso. Nessuno dei nervi ricostruiti ha riguadagnato la sua funzione, benché sia stato conservato un buon tono muscolare. In 23 dei 38 nervi intatti (61%) è stato osservato un buon recupero funzionale. La motilità laringea è stata recuperata bilateralmente solo in quattro pazienti. In tutti i casi la ripresa funzionale del nervo si è verificata entro 3 mesi dalla chirurgia primaria. La revisione chirurgica immediata in caso di sospetta paralisi ricorrente bilaterale dopo tiroidectomia può aiutare a precisare il tipo del danno a carico dei ricorrenti, predittivo del recupero funzionale, e fattore principale nel determinare i successivi passi terapeutici.

PAROLE CHIAVE: Paralisi ricorrente bilaterale della laringe • Revisione chirurgica immediata • Recupero funzionale • Chirurgia della tiroide

Acta Otorhinolaryngol Ital 2012;32:222-228

Introduction

Diseases of the thyroid and parathyroid glands are the most frequent endocrinopathies, while the incidence of thyroid gland malignancies is rising. According to epidemiological studies, about 10% of the adult population will experience a thyroid or parathyroid pathology requiring regular follow-ups or treatment¹, and thyroid and parathyroid gland surgery is very common. Nevertheless, these surgeries are associated with potentially dangerous and potentially life-threatening complications that can bear lifelong health consequences

History of thyroid surgery dates back more than 100 years. Mortality rates have decreased significantly, from more than 50% in Kocher's times to far less than 1% in modern thyroid surgery. In addition to postoperative bleeding and injury to the parathyroid glands, damage to the recurrent laryngeal nerve (RLN) remains the most feared complication with very serious functional sequelae for the patient. Unilateral vocal cord paralysis/paresis leads to a poor quality of voice and swallowing problems, whereas bilateral vocal-cord immobility can cause potentially life threatening airway obstruction.

Thyroid surgeons have always tried to establish a safe method for intervention of the thyroid and parathyroid glands and to not compromise the RLN. Identification of the RLN and its meticulous dissection has been shown to reduce the frequency of RLN palsy^{2,3}. Various methods of RLN identification have been described^{4,5}. Intraoperative monitoring was developed to facilitate RLN identification in an attempt to reduce the frequency of its injury. Even if there are no studies affirming a clear connection between RLN monitoring and decreased frequency of RLN damage⁶, it is generally agreed that neuromonitoring represents a useful tool in cases of large multinodular goiters, malignancies, revision surgeries and paediatric thyroid surgery^{7,8}. International guidelines for intraoperative neuromonitoring have been published recently^{9,10}.

The overall frequency of permanent RLN palsy varies from 0% to nearly 2% in the majority of specialized centres^{3,11}; the reported frequency of early postoperative bilateral nerve palsy is very low, usually less than 0.5%¹². Furthermore, the probability of the restoration of impaired function of the nerve ranges from 35-60%. The majority of the available data have been reported by authors from large centres, while data from smaller departments (probably with a higher percentage of RLN damage) with fewer patients are entirely missing.

The outcome of patients with bilateral RLN palsy is always of main concern for the surgeon. Because the occurrence of this complication is very seldom and unpredictable in the majority of cases, it is difficult to design and carry out a prospective study dealing with this problem. However, for both the patient and surgeon, the likelihood of functional recovery plays a crucial role in determining further therapeutic management.

The present study documents findings in a cohort of patients undergoing revision surgery for bilateral RLN palsy, and also evaluates the recovery potential of injured nerves.

Materials and methods

From January 1, 2004 to January 30, 2011, 29 consecutive patients underwent revision surgery for suspected bilateral vocal cord palsy after total thyroidectomy at the Department of Otorinolaryngology, Head and Neck Surgery, Faculty Hospital Motol, Postgraduate Medical School, First Faculty of Medicine, Charles University in Prague, Czech Republic. The vast majority of revision surgeries (93% of all cases) were performed by two highly experienced thyroid surgeons, both rated as experts in thyroid surgery (with more than 4000 and 3000 thyroid interventions), while the remaining two cases were performed by thyroid surgeons with somewhat less experience (200-500 cases). The author's department is a tertiary referral centre and a centre for thyroid and parathyroid surgery with more than 800 cases performed per year. The overall incidence of permanent unilateral and temporary and permanent bilateral laryngeal paralysis after thyroid and parathyroid surgery at our institution in the same period (2004-2011) was 2.4%, 0.125 and 0.018%, respectively.

The study cohort comprised 29 patients, 2 males and 27 females. Patients were aged 23 to 76 years at the time of surgery; median age was 52 years. Diagnosis of RLN bilateral palsy was confirmed endoscopically in all cases within a maximum of 6 hours following thyroid surgery, usually at the department where the original surgery was performed. Whenever possible, patients in good respiratory condition were not re-intubated until revision surgery. During revision surgery, because of the bilateral RLN palsy, a thorough search for the nerve and its branching was conducted on both sides. Identification of the type and extent of injury of each branch was reported in the protocol of each procedure. Every possible effort to reconstruct the transected nerve was made. All procedures were performed under magnification. A surgical microscope was used for evaluation of the RLN lesion and for reconstruction of the damaged RLN in 96% of cases and in 100% of reconstructions, respectively.

Based on the patient's overall health status, nature of RLN lesion and predicted possibility of functional recovery, patients were either extubated at the operating theatre or a tracheotomy was performed. All patients were given a short (4-5 days) course of postoperative corticosteroids (methylprednisolone sodium succinate 125-250 mg/day i.v.).

Patients were observed postoperatively at the ICU. After discharge, all patients were followed-up for at least 12 months. Videolaryngostroboscopy and/or laryngeal videokymography was performed during follow-up. Quality of voice was subjectively graded with the GRBAS evalu-

ation scale by experienced listeners. The voice handicap index (VHI, Czech validated version) was employed to evaluate the impact of voice quality on the quality of life. RLN palsy was defined as reduced mobility or a completely immobile vocal cord. RLN palsy was regarded permanent if it persisted for more than 12 months. All patients underwent the recommended postoperative speech therapy.

Functional recovery potential was estimated based on intraoperative findings.

Results

Primary surgeries were performed in nine different departments. Seven of the 29 cases had undergone primary surgery in the author's department. All patients were referred for the revision surgery immediately after diagnosis of bilateral RLN palsy. All the surgical procedures were primary operations.

Primary thyroid gland surgery was complete total thyroidectomy in 27 patients (93%). Total hemithyroidectomy with simultaneous removal of the hyperfunctioning adenoma of the parathyroid gland on the contralateral side was performed in two cases. In one patient with differentiated papillary thyroid cancer and metastatic involvement of left cervical lymph nodes, unilateral selective neck dissection II-VI was also performed.

Results of histopathology revealed non-malignant multinodular goiter in 21 cases (72%), chronic Hashimoto-type thyroiditis in four cases (14%), papillary thyroid cancer in three cases (10%) and malignant lymphoma of the thyroid gland in one case (3%). In two cases, a parathyroid gland adenoma was searched for and removed together with a multinodular goiter. Malignant lesions were comprised in the thyroid gland lobe, except one case in which 3 cm of the left RLN was macroscopically infiltrated (as the tumour invaded the nerve it was resected deliberately).

All revision surgeries were performed within 24 hours following the primary surgical procedure. Revisions were done under general anaesthesia; patients were intubated trans-orally. In one case, tracheotomy was performed immediately after the thyroidectomy elsewhere because of imminent suffocation. Every effort to identify the nature and extension of injury to RLN was made. Whenever possible, direct end-to-end, tension free anastomosis was performed if the nerve was transected. Intraoperative neuromonitoring of RLN was used in 5 cases; this relatively low frequency is due to the limited availability of a neuromonitoring device. The RLN on both sides were identified in all cases.

Complete transection of the nerve was identified in 14 cases. In another five patients, only the anterior branch of RLN was found to be discontinuous. In three patients, the main trunk of the nerve or some of its branches was completely or partially transected on both sides.

Primary end-to-end anastomosis was performed in seven completely transected RLN and four transected anterior

branches of RLN of 19 transected nerves. Seven completely transected nerves and one anterior branch of RLN were not reconstructed due to unfavourable anatomical situations. In such cases, only a small or any identifiable portion of the distal nerve stump was present, and we found it technically impossible to perform neurorrhaphy. In seven cases, an anatomically intact nerve was injured by loaded ligature, and in one case there was a sign of thermal damage. Four nerves displayed signs of excessive manipulation (missing perineural sheet, artificial thinning of nerve trunk etc.).

During five revision surgeries, a neuromonitoring device was available. Intact nerves on both sides with positive response were identified in three patients; however, only two nerves restored their function. In another two cases, neuromonitoring was very helpful for identification of the transected nerve stumps.

Eleven patients were tracheotomized, 10 after the revisional surgery at our department, while one was tracheotomized elsewhere after the primary surgical procedure. Eight tracheotomized patients were eventually decannulated. Five regained vocal cord mobility on at least one side (two on both sides), one patient underwent endoscopic posterior cordotomy and two were able to breathe with only minor difficulties.

There were 38 nerves that were found to be intact during the revision procedure. Nevertheless, only 23 of these 38 nerves (61%) has complete restoration of function, and normal vocal-cord mobility on the both sides was restored in only four patients. In all cases with regained vocal-cord mobility, functional recovery occurred within 3 months following the primary surgery. Detailed data are summarized in Table I.

Videokymographic studies demonstrated that the mucosal wave of the immobile vocal cord was usually quite shortened and had lower amplitude; in cases with inadequate muscular tone, there was a side-shift of the mucosal wave border to the paralyzed side. A contralateral mucosal wave was pronounced with the medial border shifted towards the immobile vocal cord. Glottic insufficiency was observed in patients with less muscle tone of the affected vocal cord. Insufficient muscle tone was obviously found in cases with interrupted and unreconstructed nerves. Vibratory patterns of vocal cord mucosa were related to vocal cord position in patients with persistent bilateral RLN paralysis. Interestingly, in cases with pure paramedian position and good vocal muscle tone, mostly symmetrical mucosal waves were observed on videokymography. Videolaryngostroboscopy provided similar results in cases whenever it was possible to establish a relatively stable frequency of voice and regular vibration. Follow-up visits revealed that most re-sutured nerves had relatively good tone of vocal muscle and displayed little or no atrophy.

Consistent with the above-mentioned findings, there were changes in the quality of voice subjectively evaluated using the GRBAS scale. Scoring also changed over time as

Table I. Patient characteristics.

Age	Sex	Surgeon of the primary procedure	Histology	Revision right	Revision left	NeMo	Motility right	Motility left	TRST	CE
67	F	Experienced	MNG	Trans ABRLN, suture	Partial trans, suture	No	No	No	Yes	No
76	M	Experienced	MNG	Trans, no reconstr	Trans, no reconstr	No	No	No	Yes	No
64	F	Intermediate	Tox, MNG	Trans, suture	Trans, suture	Yes	No	No	No	No
52	F	Intermediate	PTC	Intact	Intact, thinner	No	No	Yes	No	No
55	F	NA	Hashimoto thyroiditis	Intact, oedema	Intact, oedema	Yes	No	No	Yes	No
50	F	Intermediate	MNG	Trans, suture	Trans ABRLN, suture	Yes	No	No	Yes	Yes left
78	F	Experienced	PTC	Intact	Trans, infiltration, no reconst	No	Yes	No	Yes	No
49	F	Intermediate	Tox, MNG	Intact, thinner	Trans, no reconstr	No	Yes	No	Yes	No
44	F	Intermediate	Hashimoto thyroiditis	Intact	Intact	No	Yes	Yes	Yes	No
60	F	Intermediate	Hashimoto thyroiditis	Intact	Intact	No	No	No	No	No
24	F	NA	lymphoma	Intact	Intact	No	No	No	No	No
43	F	Intermediate	MNG	Intact, caut	Intact, thinner	No	No	No	No	No
63	F	Expert	MNG, PTH adenoma	Intact	Trans, no reconstr	No	No	No	No	No
50	F	NA	MNG	Intact	Trans, suture	No	No	No	Yes	No
42	F	Intermediate	MNG	Intact	Intact	Yes	No	Yes	No	No
58	F	Intermediate	MNG	Intact, ligature	Intact	No	No	Yes	No	No
52	F	Intermediate	MNG	Intact, compression	Intact	Yes	No	Yes	No	No
71	F	Intermediate	Hashimoto thyroiditis	Trans	Intact	No	No	Yes	No	Yes left
27	F	NA	Tox, MNG	Trans ABRLN, suture	Intact	No	No	Yes	No	No
67	F	Intermediate	MNG, PTH adenoma	Trans ABRLN, intact PBRLN, no suture	Intact	No	No	Yes	Yes	No
45	F	Intermediate	MNG	Trans, no reconstr	Intact	No	No	Yes	No	No
60	F	Intermediate	MNG	Intact, ligature	Trans ABRLN, intact PBRLN	No	Yes	No	No	No
56	F	Intermediate	MNG	Intact, close ligature	Trans, suture	No	Yes	No	No	No
50	F	Intermediate	MNG	Intact, ligature, pinched	Intact	No	Yes	No	No	No
26	F	Intermediate	MNG	Intact, thinning	Trans, suture	No	Yes	No	No	No
23	F	Intermediate	MNG	Intact, ligature	Trans, no reconstr	No	Yes	No	No	No
65	M	Intermediate	PTC	Intact, close ligature	Intact	No	Yes	Yes	No	No
50	F	Intermediate	MNG	Intact, ligature	Intact, ligature	No	Yes	Yes	No	No
57	F	Intermediate	MNG	Intact	Intact	No	Yes	Yes	Yes	No

MNG = multinodular goiter; PTH adenoma = parathyroid adenoma; ABRLN = anterior branch of recurrent laryngeal nerve; PBRLN = posterior branch of recurrent laryngeal nerve; trans = transection; NeMo = neuromonitoring; TRST = tracheostomy; CE = cordectomy/cordotomy

some of patients regained vocal-cord motility or underwent speech therapy. The same applies for patients' self-assessment using VHI scores, and in particular the emotional domain had better scores after restoration of vocal-cord mobility and after decannulation. Maximum phonation time (MPT) at first evaluation (T0) ranged from 6.5 to 13.5 sec (median 7.4 sec). Patients with persistent bilateral vocal fold immobility showed slight improvement (range 9-12 sec, median 10 sec). There were no significant differences between patients with intact and interrupted nerves. Only two patients experienced swallowing difficulties during the immediate postoperative period (first 2-3 weeks), which resolved spontaneously over time without additional treatment.

Discussion

The number of publications relating to thyroid disorders and their treatment is overwhelming, and those focusing on the therapy of bilateral RLN palsy have begun to appear with time. Despite this, information about the possibility of immediate revision in the case of iatrogenic bilateral vocal cord immobility after thyroid or parathyroid surgery is still lacking, and the majority of published studies have focused on the improvement of airway patency and its effects on quality of voice. Since bilateral RLN palsy is very uncommon, in smaller institutions this complication would not be expected to occur more than once every two to three years. If

the estimated frequency of bilateral RLN palsies is less than 0.5%, it is a very rare situation even in specialized centres, where 400-800 interventions on the thyroid and parathyroid glands are performed annually. Sometimes, the clinical appearance of the patient with such a condition is not typical, and voice changes can be attributed to direct injury to the vocal cords from the endotracheal tube. Patients with an intermediate position of vocal cords can have little or no breathing difficulties at rest. This can cause delay in the diagnosis of bilateral RLN palsy. In our institution, diagnosis of bilateral vocal cord palsy is usually performed endoscopically using either flexible endoscopes or videoendoscopes. In the current series, we were able to perform videolaryngostroboscopy or high-speed laryngoscopy in most cases. Figure 1 describes an overview of our diagnostic and treatment algorithm.

We strongly believe that in these rare cases there is a role for immediate revision based on our experience. More than 1500 surgical interventions on thyroid and parathyroid glands are carried out in our hospital annually, and approximately 800 interventions are performed in the author's department every year. Moreover, we serve as a centre for revision thyroid surgery for the entire country. We prefer to perform direct end-to-end anastomosis of the RLN or anastomosis with use of a nerve cable graft, and we have never used anastomosis with ansa cervicalis, hypoglossal nerve or different types of neuromuscular transfer. In most unreconstructed cases, the distal stump of the nerve was unidentifiable or severely damaged such that it was impossible to perform any kind of reconstruction.

Recent technical developments in laryngeal neuromonitoring and its commercial availability has lead to hypothesis that further reduction of laryngeal nerve injury is possible. However, some of the recently published articles have not been yielded highly optimistic results, although it is generally accepted that in selected situations neuromonitoring is quite useful and reduces postoperative morbidity related to RLN injury. Re-operation, retrosternal goiter and surgery for thyroid malignancy were identified as high-risk operations¹³. We also found monitoring to be extremely useful in paediatric thyroid surgery. Interestingly, in the present series the majority of patients had simple multinodular goiter, and none was re-operated. Inexperienced and intermediate thyroid surgeons could also benefit from the use of neuromonitoring. For less experienced surgeons, neuromonitoring could facilitate RLN identification and its dissection. We concur that thyroid surgeons can be divided into four groups: A) inexperienced with less than 200 thyroid surgeries; B) intermediate with 200-500 cases; C) experienced with 500-1500 cases; and D) experts with more than 1500 cases. Intermediate thyroid surgeons are statistically most prone to cause RLN injury. In concordance with this hypothesis, the majority of interventions with consequent bilateral RLN palsy in this study were performed by intermediate thyroid surgeons.

Laryngeal neuromonitoring has the potential to overcome the long learning period and reduce postoperative complications. Experienced and expert surgeons probably do not benefit from neuromonitoring as much, although it can simplify the surgical procedure in complex cases. We also found it very helpful for revision thyroid surgery for bilateral RLN palsy. Our experience confirms that intraoperative neuromonitoring is extremely sensitive and facilitates RLN identification. Its predictive role in terms of a RLN functional recovery, however, seems to be limited⁹.

Several recent studies have also shown that terminal part of RLN and its anastomoses with superior laryngeal nerve represent, with very little exaggeration, a plexus rather than a branching nerve. Kruse¹⁴ described patterns of division of the RLN and its connections with the superior laryngeal nerve in a cadaver study. According to his observation, the first (most proximal) branch of RLN is the inferior portion of Galen's ansa in the majority of cases. Very small and not very constant branches from its second ramification supply the posterior cricoarytenoid muscle. Only then does the RLN bifurcate into an anterior branch supplying vocal muscle and a lateral cricoarytenoid muscle and posterior branch that usually runs towards the interarytenoid muscle. Variability of RLN branching is the background for different vocal cord position in RLN paralysis, so-called Wagner-Grossmann theory¹⁵. Especially small branches for the posterior cricoarytenoid muscle can be readily injured during the dissection of the anterior and posterior branch of RLN. This can lead to description of intact RLN or intact posterior branch of RLN, and was probably one of the reasons why none of the cases with reported preserved posterior branch of RLN regained function. RLN paralysis in patients with anatomically intact nerve probably occurs due to excessive manipulation and stretching of the nerve, damage to the delicate vasa nervorum and oedema. (neuropraxis). Unidentified extralaryngeal division of the RLN might be another cause.

Further therapeutic steps are planned according to intraoperative findings. First of all, it is necessary to decide whether the airway should be secured by tracheotomy. The decision-making process is not always straightforward. We try to tailor intra- and postoperative measures to best suite the patients' general health status and needs. Generally speaking, we try to avoid tracheostomy whenever there is evidence of anatomically intact nerve on at least one side, but patients in poor general health (morbid obesity, cardiovascular and pulmonary diseases, severe neurologic and psychiatric disorders) are good candidates for tracheotomy. Therefore, the subgroup of patients tracheotomized during the surgical procedure is rather inhomogeneous. Seven of these patients had at least one RLN intact (not transected), while two of them had even intact nerves on both sides. The functional recovery potential of these cases is considered very high. Furthermore, younger non-obese patients without significant comorbidities do not need tracheotomy

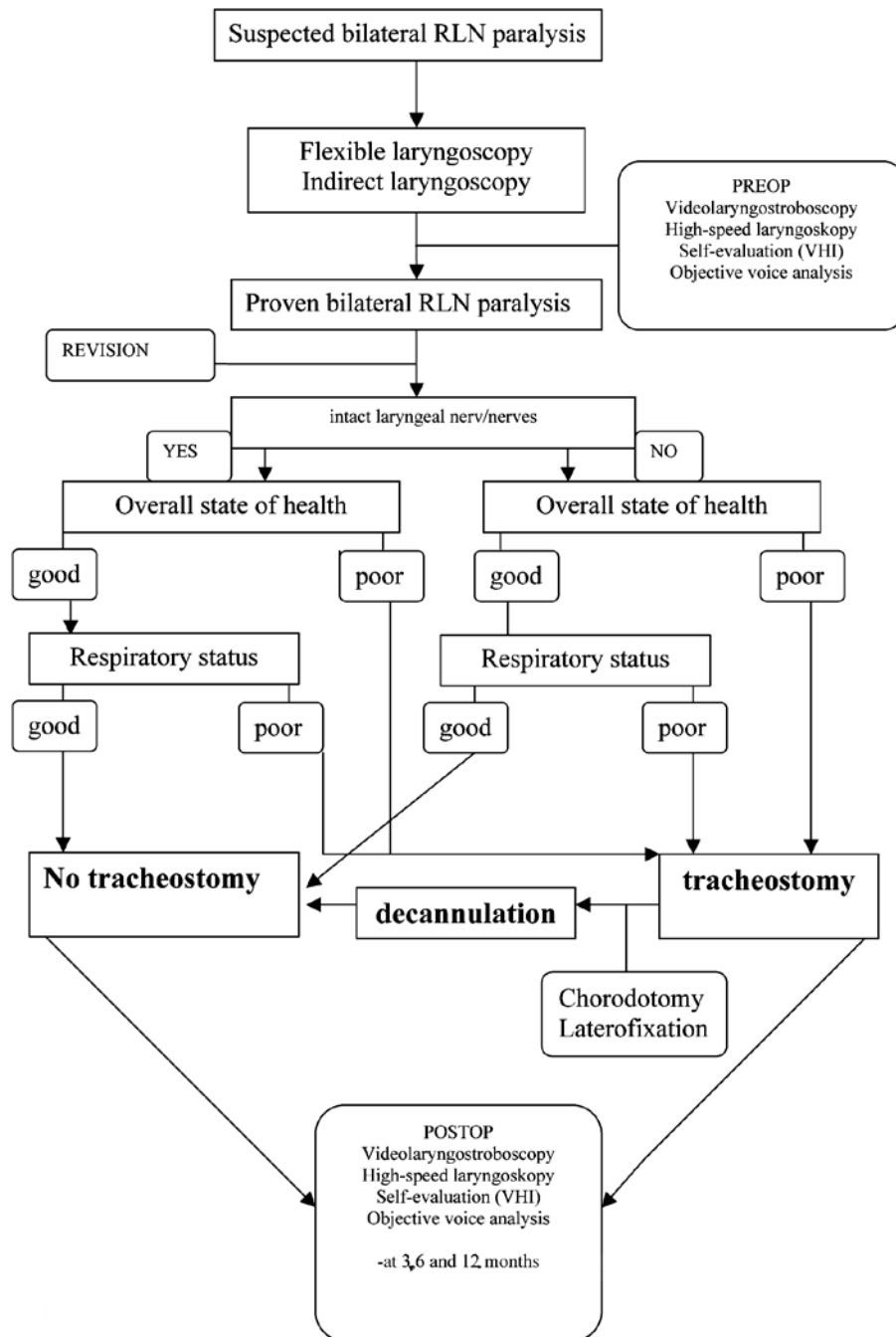


Fig. 1. Diagnostic and treatment algorithm.

in many cases. In our series, three patients that fit these conditions were tracheotomized because of altered general health status (multiple commorbidities, high BMI, etc.), and in another four in generally good conditions due to significant inspiratory stridor and airway compromise. The remaining three patients with nerve continuity interrupted on both sides were planned to undergo some kind of airway enlargement procedure. Seven patients were decannulated within six months after surgery, and 6 of these had at least one RLN intact (both in two cases). One patient with both the RLN transected and reconstructed was decannulated after the left sided posterior chordotomy was performed, and

the patient was able to breathe without difficulties. Eighteen patients in the subgroup of non-tracheotomized patients (19 patients) had at least one RLN intact, with 10 having both intact. As shown, the potential for functional recovery of these patients is very high and therefore there is no need for airway enlargement procedures. As such, if there is no acute airway distress, further surgical steps should not be attempted. If nerve function is restored, it occurs in most cases within four to six months after surgery¹⁶. There was also one patient with bilateral transection of RLN in good general health status who had minimal respiratory problems due to the favourable anatomical position of vocal cords.

None of the reconstructed nerves (completely transected) regained function (vocal-fold mobility), although good muscle tone was described in the majority of performed neuroorrhaphies. Interestingly, any reconstruction of the anterior branch of RLN led to restored partial or complete mobility of the vocal cord.

Available vidolaryngostroboscopic and videokymographic findings documented recovery of vocal cord mucosal waves (including their phase and symmetry) in all four cases with restored bilateral mobility. Symmetry in vibratory patterns on stroboscopic or videokymographic evaluation seemed to demonstrate complete functional recovery, even though this is not a prerequisite of normal voice¹⁷. In cases where unilateral vocal cord immobility persisted, we usually observed asymmetry in mucosal waves and phase shift. This typical counter-striking pattern of mucosal waves movement has already been reported elsewhere¹⁸.

Conclusions

Immediate revision surgery in iatrogenic bilateral RLN palsy is beneficial for patients with unclear integrity of the RLN after thyroid or parathyroid surgery, and can help to identify patients with higher probability of recovery of vocal-cord mobility. Reconstruction of the nerve may help to maintain the correct volume and muscle tension, which is beneficial in patients with persistent vocal cord immobility. Surgery should be performed as soon as possible after primary intervention; best results are obtained if the surgery is performed within 24 hours. Surgery is very demanding and significantly affects both the patient and surgeon. Therefore, it should be exclusively reserved for specialized centres and performed by expert surgeons in thyroid surgery.

This study was supported by the grant NS 9901 of the Internal Grant Agency of the Ministry of Health of the Czech Republic.

References

- 1 Canaris GJ, Manowitz NR, Mayor G, et al. *The Colorado thyroid disease prevalence study*. Arch Intern Med 2000;160:526-34.
- 2 Steurer M, Passler C, Denk DM, et al. *Advantages of recurrent laryngeal nerve identification in thyroidectomy and parathyroidectomy and the importance of preoperative and postoperative laryngoscopic examination in more than 1000 nerves at risk*. Laryngoscope 2002;112:124-33.
- 3 Hermann M, Alk G, Roka R, et al. *Laryngeal recurrent nerve injury in surgery for benign thyroid diseases: effect of nerve dissection and impact of individual surgeon in more than 27,000 nerves at risk*. Ann Surg 2002;235:261-8.
- 4 Procacciante F, Picozzi P, Pacifici M, et al. *Palpatory method used to identify the recurrent laryngeal nerve during thyroidectomy*. World J Surg 2000;24:571-3.
- 5 Wang C. *The use of the inferior cornu of the thyroid cartilage in identifying the recurrent laryngeal nerve*. Surg Gynecol Obstet 1975;140:91-4.
- 6 Higgins TS, Gupta R, Ketcham AS, et al. *Recurrent laryngeal nerve monitoring versus identification alone on post-thyroidectomy true vocal fold palsy: a meta-analysis*. Laryngoscope 2011;121:1009-17.
- 7 Hermann M, Hellebart C, Freissmuth M. *Neuromonitoring in thyroid surgery: prospective evaluation of intraoperative electrophysiological responses for the prediction of recurrent laryngeal nerve injury*. Ann Surg 2004;240:9-17.
- 8 Dralle H, Sekulla C, Lorenz K, et al. *Intraoperative monitoring of the recurrent laryngeal nerve in thyroid surgery*. World J Surg 2008;32:1358-66.
- 9 Chan WF, Lo CY. *Pitfalls of intraoperative neuromonitoring for predicting postoperative recurrent laryngeal nerve function during thyroidectomy*. World J Surg 2006;30:806-12.
- 10 Randolph GW, Dralle H, Abdullah H, et al. *Electrophysiologic recurrent laryngeal nerve monitoring during thyroid and parathyroid surgery: international standards guideline statement*. Laryngoscope 2011;121(Suppl 1):1-16.
- 11 Lo CY, Lang BH, Chan WF, et al. *A prospective evaluation of preoperative localization by technetium-99m sestamibi scintigraphy and ultrasonography in primary hyperparathyroidism*. Am J Surg 2007;193:155-9.
- 12 Bhattacharyya N, Fried MP. *Assessment of the morbidity and complications of total thyroidectomy*. Arch Otolaryngol Head Neck Surg 2002;128:389-92.
- 13 Chan WF, Lang BH, Lo CY. *The role of intraoperative neuromonitoring of recurrent laryngeal nerve during thyroidectomy: a comparative study on 1000 nerves at risk*. Surgery 2006;140:866-72.
- 14 Kruse E, Olthoff A, Schiel R. *Functional anatomy of the recurrent and superior laryngeal nerve*. Langenbecks Arch Surg 2006;391:4-8.
- 15 Grossmann M. *Experimentelle Beiträge zur Lehre von der "Posticuslähmung"*. Arch Laryngol u Rhin 1897;6:282.
- 16 Thermann M, Feltkamp M, Elies W, et al. *[Recurrent laryngeal nerve paralysis after thyroid gland operations. Etiology and consequences]*. Chirurg 1998;69:951-6.
- 17 Shaw HS, Deliyski DD. *Mucosal wave: a normophonic study across visualization techniques*. J Voice 2008;22:23-33.
- 18 Svec JG, Sram F, Schutte HK. *Videokymography in voice disorders: what to look for?* Ann Otol Rhinol Laryngol 2007;116:172-80.

Received: December 1, 2011 - Accepted: February 29, 2012

Address for correspondence: Michal Zábrodský, Charles University in Prague, First Faculty of Medicine, Department of Otorinolaryngology, Head and Neck Surgery, Faculty Hospital Motol, Postgraduate Medical School, Czech Republic, V Úvalu 84, 15006, Prague 5-Motol, Czech Republic. Tel. +420 224434357. Fax +420 224434319. E-mail: mzabrodsky@tiscali.cz